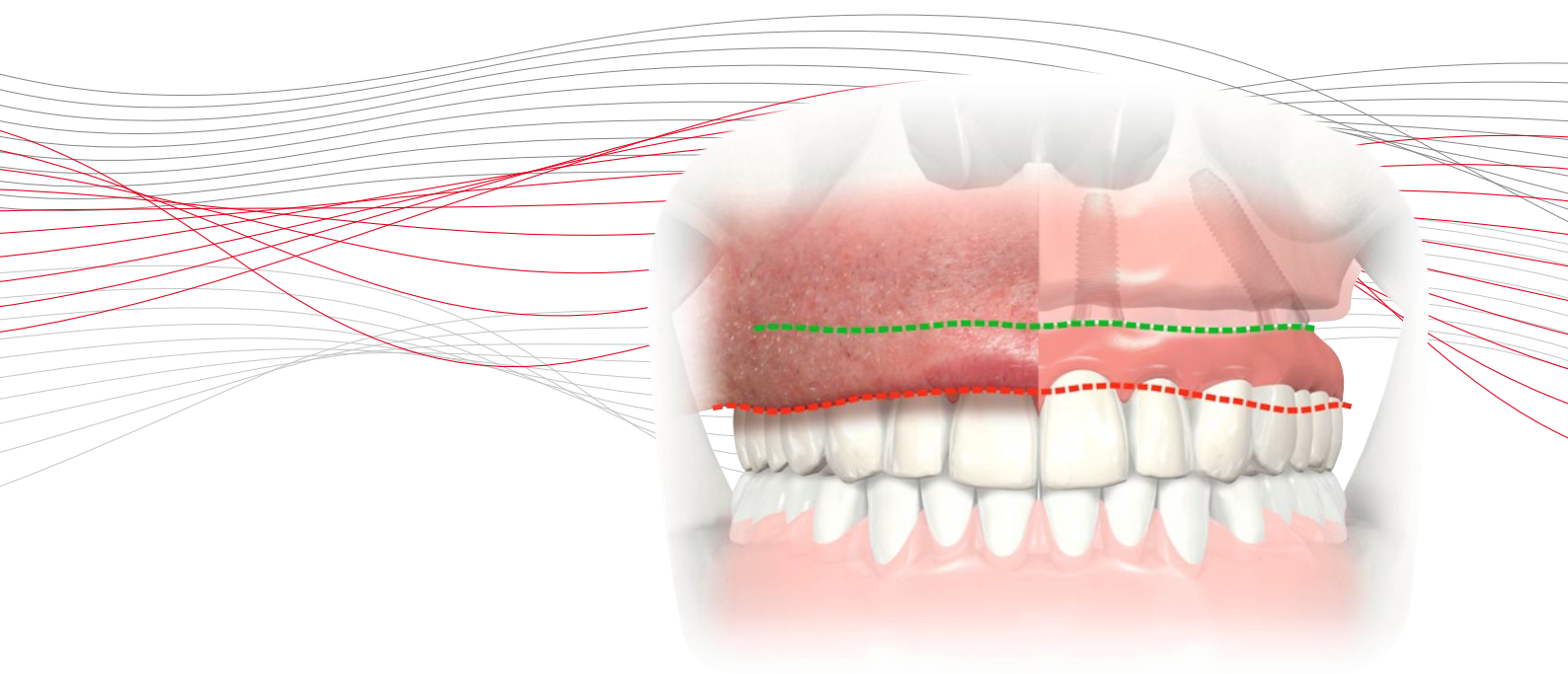


Rehabilitation concepts for edentulous patients Pre-treatment guidelines



Contents

Introduction	Comprehensive range of treatment solutions from the pioneer of osseointegration	4
	The edentulous patient – social and functional implications	5
Planning	Pre-treatment guidelines and considerations:	
	– Oral examination of the patient	6
	– Bone resorption pattern	7
	Maxilla:	
	– Treatment in the maxilla requires evaluation of available alveolar bone	8
	– Grafting and delayed loading	10
	– Transition line	11
	– Considerations for the placement of 4 versus 6 implants	12
	Mandible:	
	– Treatment of the edentulous mandible	13
3D treatment planning with NobelClinician®	14	
Guided surgery with NobelGuide®	15	
Loading of implants	16	
Immediate Function	Clinical guideline – Immediate Function with TiUnite® implants	17
Clinical cases	Mild/moderate bone resorption:	
	– Immediate loading for full-arch rehabilitation using NobelClinician®	20
	– Failing dentition in both arches	22
	Moderate bone resorption:	
	– All-on-4® treatment concept with NobelGuide® in maxilla and flap approach in mandible	24
	Moderate/severe bone resorption:	
– A predictable restorative outcome as a result of a pre-treatment evaluation method using NobelClinician®	26	
References		28

Comprehensive range of treatment solutions from the pioneer of osseointegration

In close cooperation with experienced clinicians and opinion leaders, Nobel Biocare has set the standard for integrated solutions for the treatment of edentulous patients and patients with a failing/terminal dentition. Clinicians can choose from a comprehensive range of implant-based fixed and fixed-removable restorations that can be custom designed to meet every patient's specific needs. Compared to conventional removable dentures, these implant-based solutions provide superior benefits to the patients and help them improve their quality of life.

From the restorative perspective, there is broad flexibility in the final prosthetic design. CAD/CAM designed frameworks, bridges and bars in different materials meet the different patient conditions and needs, enabling clinicians to deliver precision-milled reconstructions with a passive and excellent fit.

This guide on rehabilitation concepts for edentulous patients has been developed together with a group of experts to aid clinicians in their selection of the appropriate treatment for their patients based on the individual clinical parameters.

All treatment concepts shown in this guide are supported by scientific evidence. For more information on Quality of Life studies, scientific evidence and other related publications, please refer to page 28.



Dr. Edmond
Bedrossian
USA



Dr. Paulo Malo
Portugal



Dr. Steve Parel
USA



Dr. Enrico Agliardi
Italy



Dr. Lesley David
Canada



Dr. Charles
Babbush
USA



Dr. Hannes
Wachtel
Germany



Dr. Jack Hahn
USA

The edentulous patient – social and functional implications

The use of dental implants to improve patients' quality of life has been documented in a multitude of publications. The embarrassment caused by dentures moving during social interactions and the constant preoccupation with attempts to stabilize them leaves the majority of patients dissatisfied with this treatment option, as reported in the Quality of Life studies. The use of dental implants improves patients' speech, esthetics, function and self-esteem. The overall improvement of patients' social life, self-image, comfort as well as the internal loading of the alveolar bone halting its further resorption, make dental implants a predictable and reliable treatment option over conventional dentures.

Dental implants are well-documented to improve edentulous patients' quality of life.

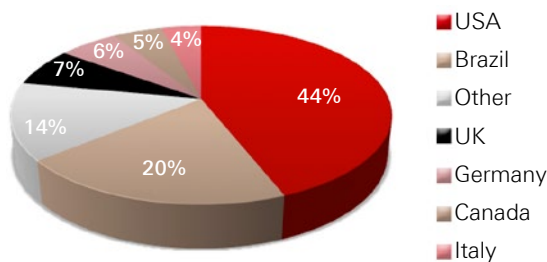
A literature review from the National Library of Medicine has described edentulism as a global issue, with estimates for an increasing demand for complete denture prosthesis in the future. Patients with complete edentulism were found to be at higher risk of poor nutrition with higher incidence of coronary artery plaque formation. Chronic residual ridge resorption continues to be the primary intra-oral complication of edentulism. Without the use of dental implants there appears to be few opportunities to reduce bone loss.

Patients with complete edentulism seem to be at risk for multiple systematic disorders if left untreated.

Edentulism is a very common handicap and there is a tremendous need for different solutions to treat this group of patients. Complete edentulism is the terminal outcome of multifactorial processes involving biological and patient-related factors. It represents a tremendous global health care burden, and will do so for the foreseeable future. The demand for treatment extends to millions of edentulous people – more than 40 million in the Western world, and 250 million in Asia. Of the total population worldwide, around 6–10% are edentulous.*

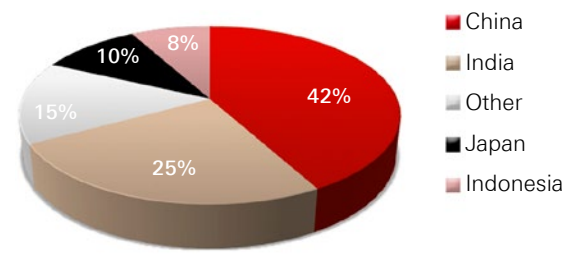
The enormous global demand for edentulous solutions will continue to increase.

Western world



40 million people are edentulous in the Western world:
64% live in the USA and Brazil.

Asia



250 million people are edentulous in Asia:
67% live in China and India.

* Source: WHO and Nobel Biocare estimates.
Visit WHO <http://www.whocollab.od.mah.se/countriesalphan.html> for more details.

Pre-treatment guidelines and considerations

– oral examination of the patient

A thorough pre-treatment evaluation of edentulous patients or patients with failing/terminal dentition is necessary to establish a predictable treatment outcome. The aim of this guide is to assist clinicians in following suggestions in a systematic format and protocol, allowing for the formulation of a comprehensive treatment plan. To begin the evaluation of this group of patients, the following may be taken into consideration:

1 Medical history and chief complaint

Any conditions that might affect the result or influence candidacy as a surgical patient are noted here. Consideration for referral for medical clearance as indicated.

2 Dental history

Ascertain the patient's expectations, past dental history with dental failure, e.g. periodontal disease, admitted or known habits including clenching and bruxing.

3 Radiographic analysis

Initial radiographic evaluation may be done with the help of a panoramic radiograph (OPG). Upon the discretion of the practitioner, a full mouth periapical series (FMX/FMS), a medical CT scan or a CBCT (cone beam CT) analysis prior to the final decision may be considered.

4 Intra- and extra-oral examination

Evaluate the condition of the remaining teeth documenting caries, occlusion, occlusal discrepancies and migration of teeth. For patients with remaining teeth, the oral examination is always based on periodontal findings and disease status of remaining teeth and soft tissue. This includes a full pocket depth charting with mobility, recession, furcation, bleeding, suppuration and apical lesions, all being noted. For both patients with partial and complete edentulism, the general and specific soft tissue conditions are also documented. The soft tissue examination identifies any palpated area observed in the oral cavity and oropharynx, as well as evaluation of the temporomandibular joint (TMJ). The smile analysis is part of the external facial examination, which includes a neck examination for any palpable lymph nodes.

5 Treatment planning

To begin a systematic pre-treatment evaluation of the patient, the following information during the evaluation may also be helpful:

- I) Presence or lack of hard and soft tissue: may aid the practitioner to determine the type of final prosthesis to fabricate.
- II) "Transition Line": determination of a hidden or visible transition line can assist in determining potential esthetic considerations and needs.
- III) "Zones/Groups of the Maxilla": could be helpful for the practitioner in presenting a particular surgical and restorative treatment protocol. For more information regarding the overview of bone resorption patterns and treatment examples, please refer to pages 8–9 in this guide.
- IV) The use of 3D software such as NobelClinician is also advisable to evaluate the potential sites for implant placement.

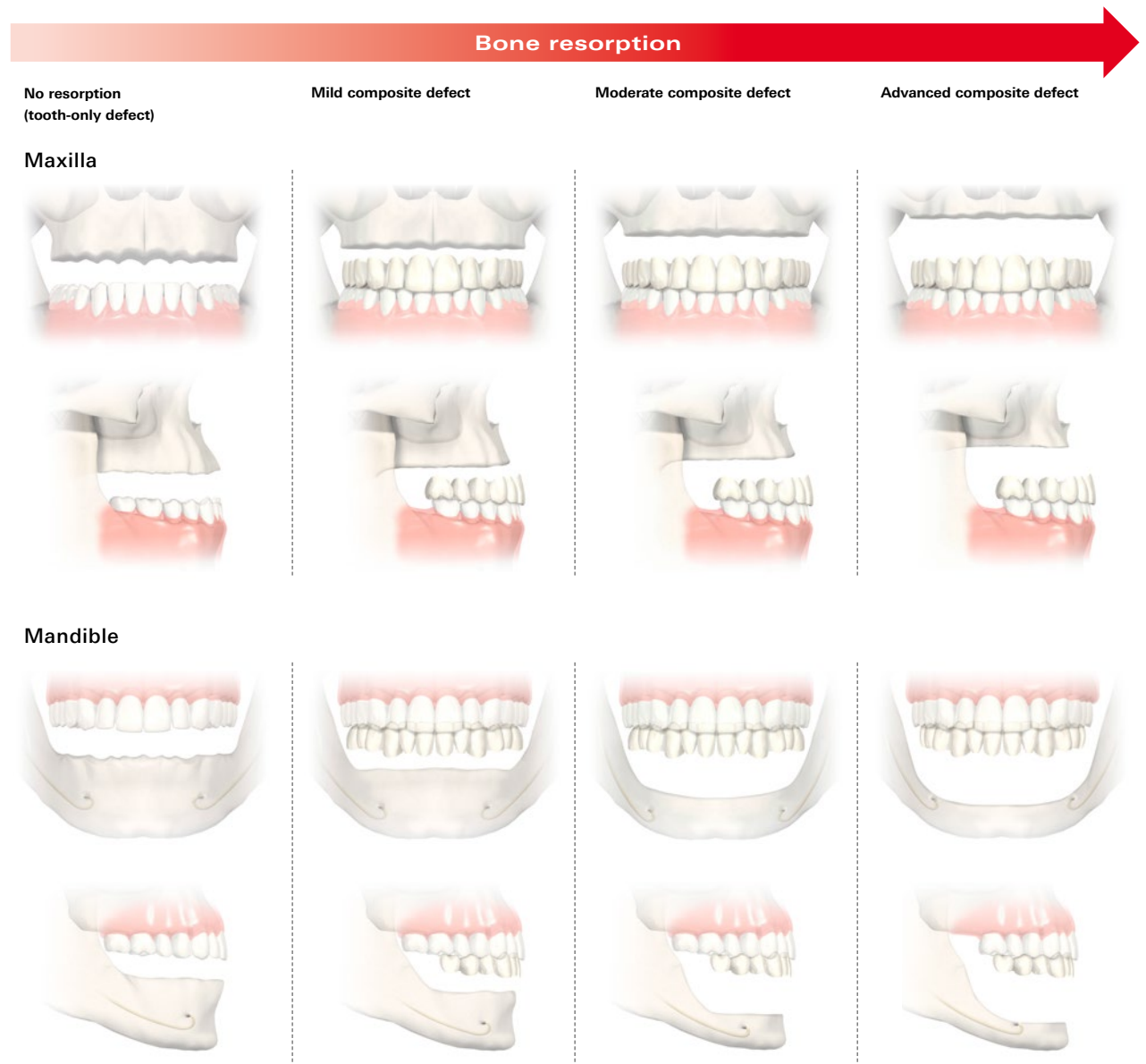
After implant treatment, an individual maintenance program (oral hygiene instructions etc.) for the patient is important to secure a favorable long-term treatment outcome.

The final phase in treatment planning includes an in-depth presentation of all appropriate treatment options. Any discrepancies in the bone or anticipated esthetic or functional limitations to proposed treatment are documented here. Final acceptance to the plan is documented with patient confirmation.

Pre-treatment guidelines and considerations – bone resorption pattern

It is very important to understand the degree of the existing volume of hard and soft tissue loss, as this degree of atrophy directs the restorative protocol. This means that the remaining alveolar bone directs the surgical protocol, which in turn supports the restorative treatment plan.

How much hard and soft tissue is missing? What is to be replaced? Is there a “Composite Defect”?*

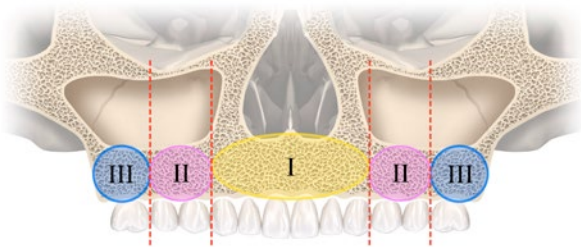


* Bedrossian E et al. Fixed-prosthetic Implant Restoration of the Edentulous Maxilla: A Systematic Pretreatment Evaluation Method. J Oral Maxillofac Surg 2008;66:112-22

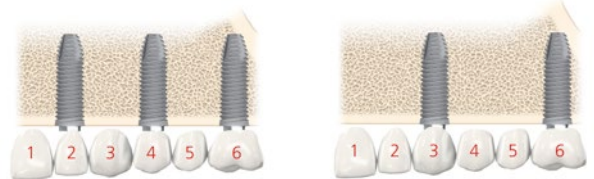Treatment in the maxilla requires evaluation of available alveolar bone



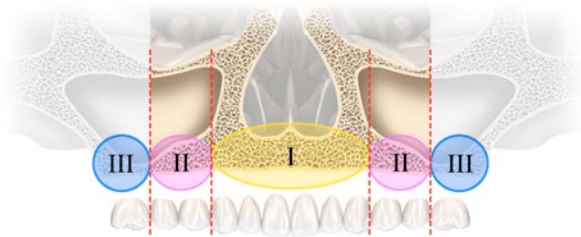
Group 1



Presence of bone in zones I, II and III



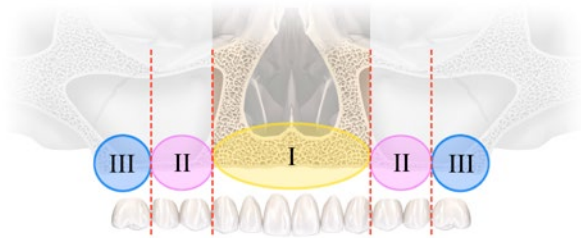
Group 2



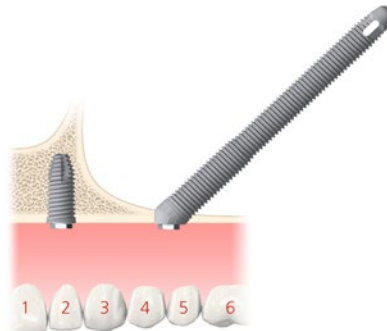
Presence of bone in zones I and II



Group 3



Presence of bone in zone I only



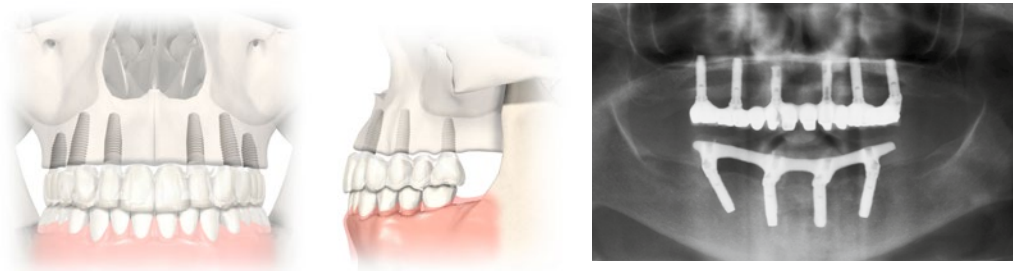
Treatment example Group 1

Surgical solution

Axial (straight) implants

Restorative solution

Screw-retained implant bridge



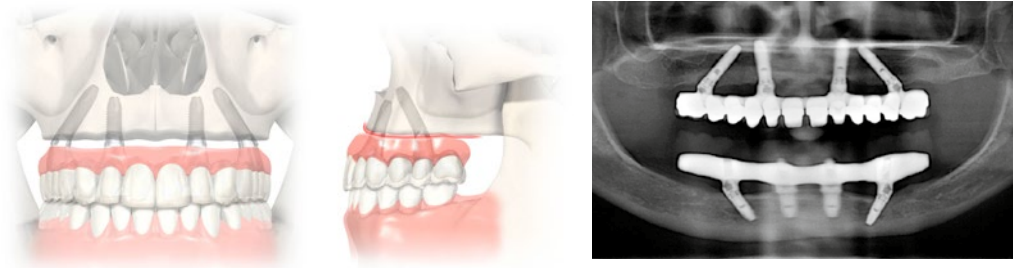
Treatment example Group 2

Surgical solution

All-on-4® treatment concept with tilted implants, bone graft or axial implants with cantilever

Restorative solution

Fixed or fixed-removable solution



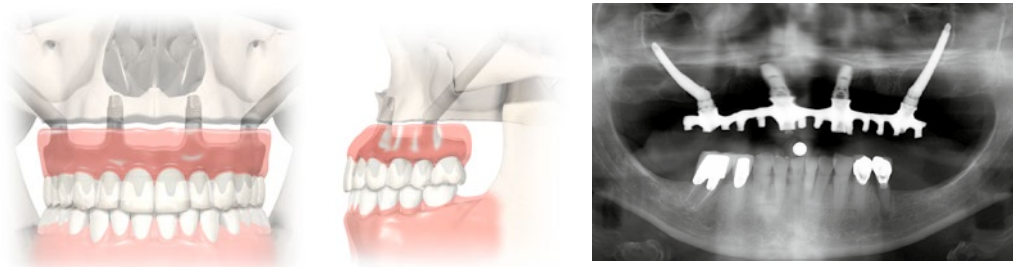
Treatment example Group 3

Surgical solution

Tilted implant concept
Brånemark System Zygoma
or bone graft

Restorative solution

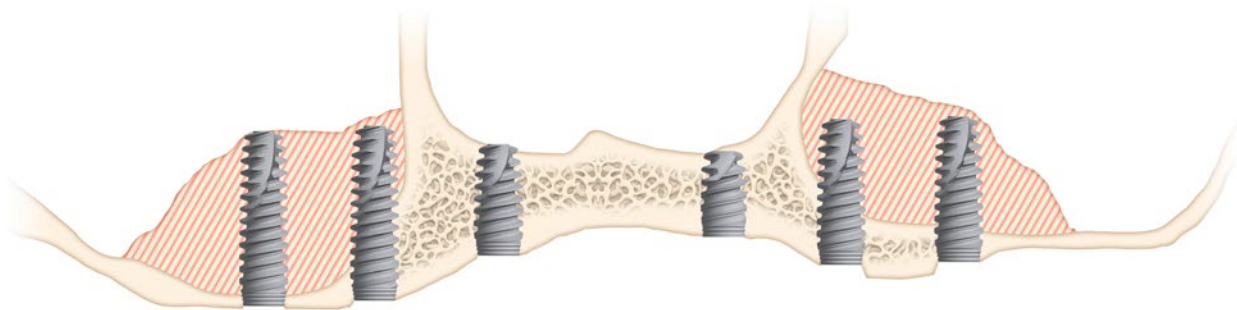
Fixed or fixed-removable
prosthesis



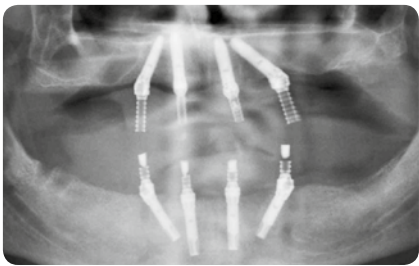
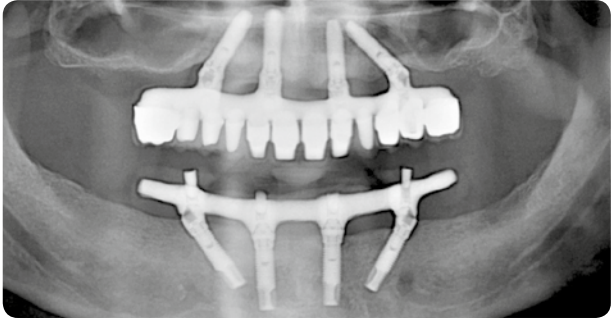
The following publications have been used as support to pre-evaluate important factors as part of the decision making process for the edentulous treatment:
 – Bedrossian E et al. Fixed-prosthetic Implant Restoration of the Edentulous Maxilla: A Systematic Pretreatment Evaluation Method. J Oral Maxillofac Surg 2008;66:112-22
 – Maló P et al. The rehabilitation of completely edentulous maxillae with different degrees of resorption with four or more immediately loaded implants: a 5-year retrospective study and a new classification. Eur J Oral Implantol 2011;4(3):227-43

Grafting and delayed loading

For patients with pneumatized sinus, the grafting of the maxillary sinus floor is certainly an option. The Consensus Report* of 1996 regards maxillary sinus grafting to be a viable procedure with a success rate of 90% or greater. However, immediate loading of these cases is not recommended and the two-stage delayed loading protocol should be followed.



Designing for Life
7-year follow-up

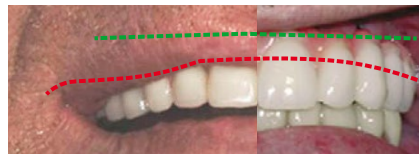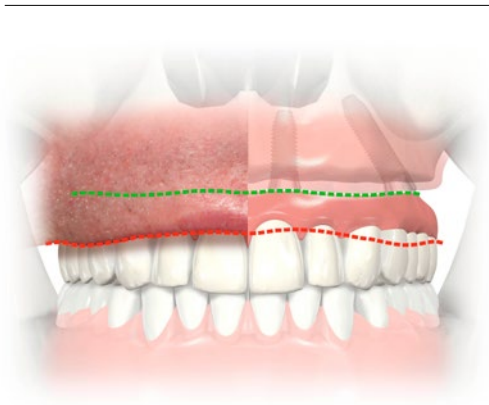



Case courtesy of Dr. Paulo Malo, Portugal

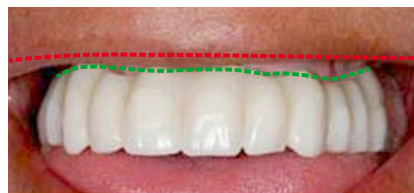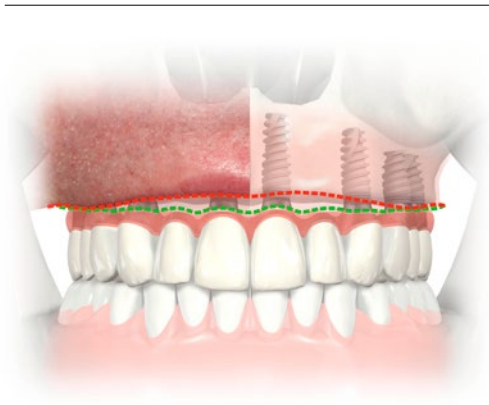
* Jensen OT, Shulman LB, Block MS, Iacono VJ. Report of the Sinus Consensus Conference of 1996. *Int J Oral Maxillofac Implants.* 1998;13 Suppl:11-45

Transition line

Evaluation of the esthetics of the final prosthesis is made by recognizing the transition line between the prosthesis and the crestal soft tissues of the edentulous ridge. If the transition line is apical to the smile line, an esthetic outcome is predictable. However, if the smile line is apical to the transition line, further evaluation should be made, as the final esthetic outcome may be compromised.



Transition line (in green) is apical to the smile line (in red) with an esthetic outcome.



Transition line (in green) is coronal to the smile line (in red) with an unesthetic outcome.

Considerations for the placement of 4 versus 6 implants

In planning the position and the number of implants to place, it is important to consider the functional and biomechanical properties of the fixed, implant-supported, final prosthesis.

As reported (Silva et al. 2010, Bevilacqua et al. 2010),* the anterior-posterior spread (AP-spread) of the implants is important in limiting or eliminating the posterior cantilever. Tilting the posterior implants (All-on-4® or Zygoma treatment concept) distalizes the implant platform (Krekmanov et al. 2000)** and a larger AP-spread is achieved, reducing the forces on the distal implants (figure 1).

However, during lateral function, increased stress values on the framework are observed, which may be addressed by the addition of two implants in the canine region (figure 2).

In the resorbed maxilla

The resorption pattern of the maxilla (dictated by the black line in figure 3) may not allow for the placement of six implants. Therefore, four implants are placed. By distributing four implants as shown in figure 3, the biomechanical properties of the final prosthesis are addressed by maintaining the AP-spread as well as lending support in lateral excursions.

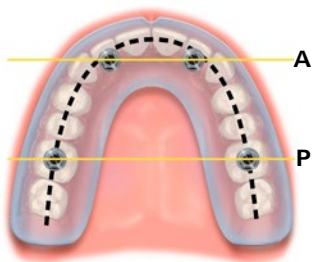


Figure 1

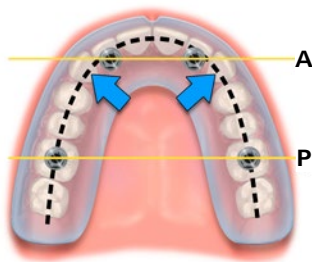


Figure 2

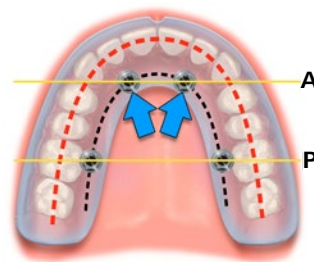
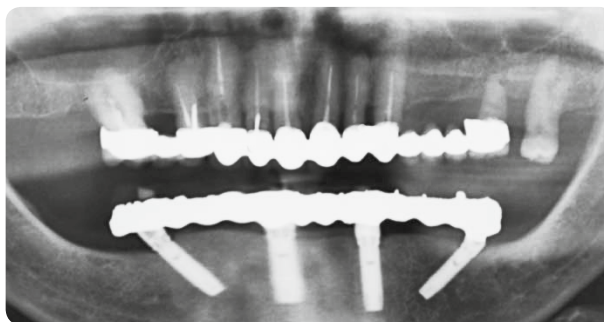
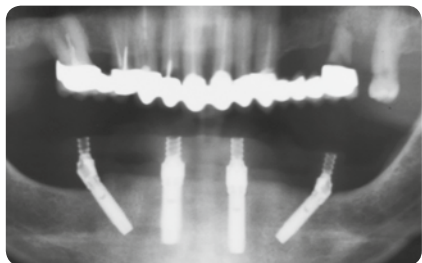


Figure 3

Designing for Life

8-year follow-up



Case courtesy of Dr. Enrico Agliardi, Italy

* Silva GC, Mendonça JA, Lopes LR, Landre J Jr. Stress Patterns on Implants in Prostheses Supported by Four or Six Implants :A Three-Dimensional Finite Element Analysis. *Int J Oral Maxillofac Implants* 2010;25:239-46

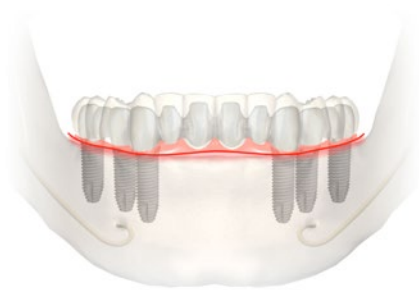* Bevilacqua M, Tealdo T, Menini M, Pera F, Mossolov A, Drago C, Pera P. The influence of cantilever length and implant inclination on stress distribution in maxillary implant supported fixed dentures. *J Prosthet Dent* 2010;105:5-13

** Krekmanov L, Kahn M, Rangert B, Lindström H. Tilting of Posterior Mandibular and Maxillary Implants for Improved Prosthesis Support. *Int J Oral Maxillofac Implants* 2000; 15:405-14

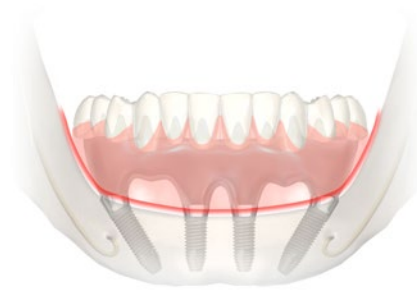Treatment of the edentulous mandible

Although it is possible to have a tooth-only defect in the edentulous mandible, most patients present some degree of bone resorption. The surgical treatment options for this group of patients include axially placed or tilted implants to support a fixed NobelProcera Implant Bridge or a fixed-removable NobelProcera Implant Bar Overdenture. The use of two axial implants to retain an overdenture in the mandible is a valid option that may also be considered.

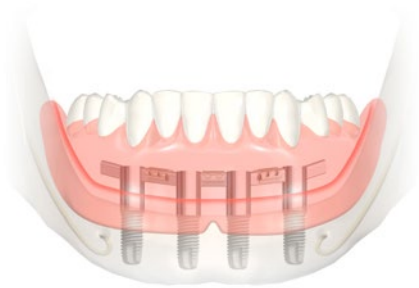Treatment examples



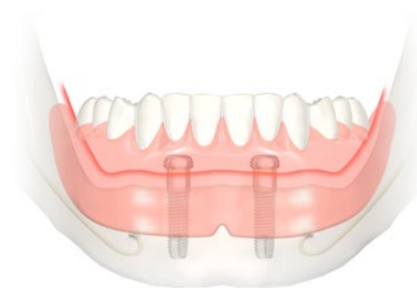Axial implants with a fixed NobelProcera Implant Bridge



Axial and tilted implants with Multi-unit Abutments and a fixed NobelProcera Implant Bridge



Axial implants with a fixed-removable NobelProcera Implant Bar Overdenture



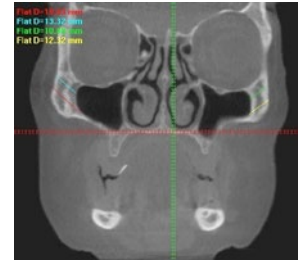Two axial implants with Locator® Abutments and a removable prosthesis

Locator® is a trademark of Zest Anchors Inc.

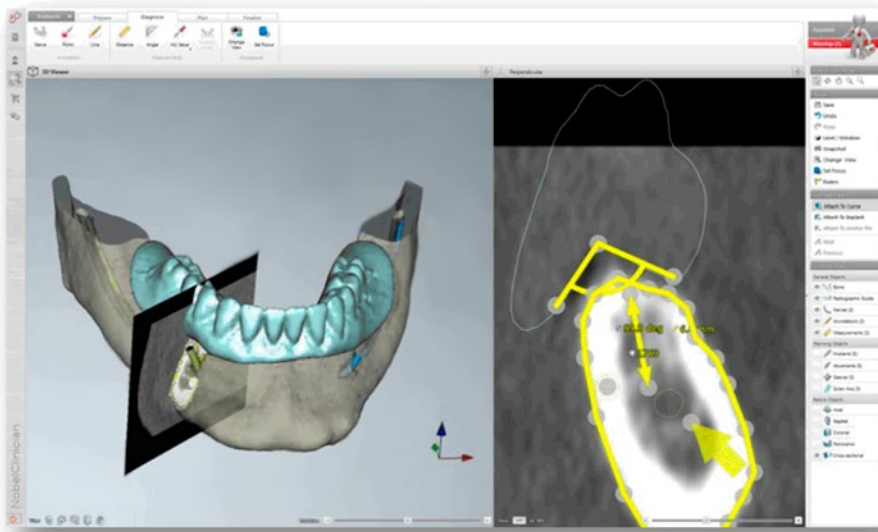
3D treatment planning with NobelClinician®

One of the key tools needed for treatment planning is the patient's radiograph. The use of the panoramic radiograph (OPG) as the scout film is indicated for all patients. In cases where further study of the patient's remaining alveolar bone is needed, a 3D study using the medical CT or CBCT (cone beam CT) scan may be obtained.

For clinicians who choose to relate the proposed implant positions to the patient's available topography of the bone, the use of the 3D treatment planning software NobelClinician is available. By importing the patients DICOM files into the NobelClinician Software, the practitioner is able to "virtually" plan the implant positions including diameter, length and angulation in a 3D environment.



CBCT frontal view



NobelClinician Software

Guided surgery with NobelGuide®

The diagnostic and treatment planning options for the clinician are enhanced by the use of the NobelClinician Software.

The software may be used in one or all of its functions:

1. Treatment plan only – NobelClinician Software
2. Designing the surgical template for guided surgery – NobelGuide treatment concept

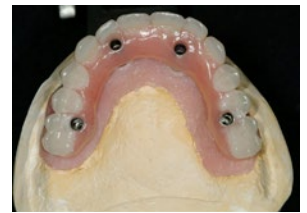After 3D treatment planning using the NobelClinician Software, the surgeon may choose to perform guided surgery with NobelGuide. A surgical template may be produced from the planning software, allowing the surgeon to perform a guided flapless or mini-flap surgical procedure.

The expanded use of the NobelGuide concept allows for preoperative fabrication of a provisional all-acrylic bridge/prosthesis, which may be immediately connected after the implants have been placed using the surgical template.

The use of the NobelClinician Software as a 3D treatment planning tool allows for a comprehensive understanding of the bony anatomy as well as the existing vital structures. It also allows for the positioning of the proposed implants onto the patient's 3D radiograph. The expanded use, the surgical template and the fabrication of an all-acrylic bridge may be an option to consider by the implant treatment team.



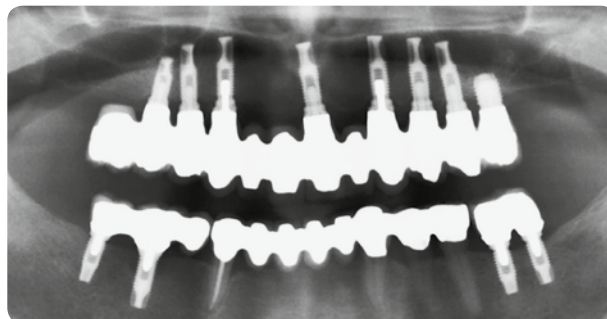
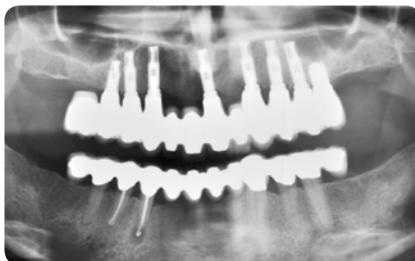
Surgical template for the All-on-4® NobelGuide treatment concept



Prefabricated all-acrylic provisional bridge

Designing for Life

16-year follow-up



Case courtesy of Dr. Hannes Wachtel, Germany

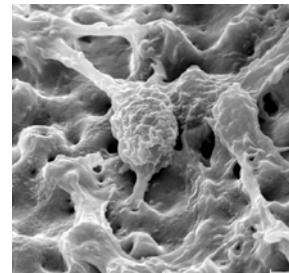
Loading of implants

After successful placement of the implants, immediate, early or delayed loading may be considered. If the two-stage approach is the treatment of choice, the patients utilize their existing dentures during the osseointegration phase. If immediate loading of the newly placed implants is desired, consider the following protocol and rationale:

Immediate loading of implants is facilitated in part by the modification of the implant surface generally referred to as "moderately rough surface". This modification has led to higher predictability when adopting the immediate load concept. Reports of high cumulative survival rates (up to 100%) have been published using the TiUnite implant surface.

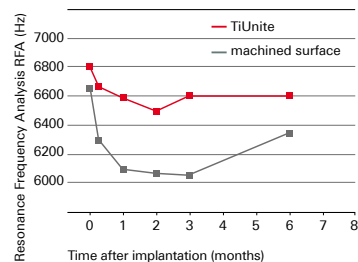
Studies have shown that the bone formation pattern on TiUnite differs from machined implants (Schüpbach et al. 2005, Zechner et al. 2003).* The difference emanates from the strong osseoconductive properties of TiUnite, which results in rapid bone growth along the implant surface and stable anchorage in surrounding bone. This is of particular importance when using the immediate load concept, and for implant treatment in soft bone and sub-optimal healing cases. Due to the formation of new bone directly on the implant surface, the mechanical stability can be maintained at a higher level throughout the healing phase compared with machined implants (Glauser et al. 2001).** Thus, TiUnite implants have allowed for higher predictability when using the immediate load concept, especially in regions with soft bone and sub-optimal healing.

The various criteria for the immediate loading of implants have been reported in the literature. Initial stability of implants is essential for a successful treatment. It is important to highlight that a minimum of 35Ncm of insertion torque is required if immediate loading is being considered. The implant has to withstand a final tightening torque of minimum 35Ncm. This can be verified by the use of the surgical manual torque wrench. If the implant does not rotate further, the initial stability of the implant is considered adequate for immediate loading.



Osteoblast on the TiUnite implant surface (courtesy of Dr Peter Schüpbach, Switzerland).

High stability in the critical healing phase



Higher stability with immediately loaded implants with TiUnite surface than with the same implants with machined surface in the posterior maxilla (Glauser et al. 2001).**

* Schüpbach P, Glauser R, Rocci A, Martignoni M, Sennerby L, Lundgren A, Gottlow J. The human bone-oxidized titanium implant interface: A light microscopic, scanning electron microscopic, back-scatter scanning electron microscopic, and energydispersive x-ray study of clinically retrieved dental implants. *Clin Implant Dent Relat Res.* 2005;7 Suppl 1:36-43

** Zechner W, Tangl S, Furst G, Tepper G, Thams U, Mailath G, Watzek G. Osseous healing characteristics of three different implant types. *Clin Oral Implants Res* 2003;14:150-7

** Glauser R, Portmann M, Ruhstaller P, Lundgren AK, Hammerle CH, Gottlow J. Stability measurements of immediately loaded machined and oxidized implants in the posterior maxilla. A comparative clinical study using resonance frequency analysis. *Applied Osseointegration Research* 2001; 2:27-9

Clinical guideline – Immediate Function with TiUnite® implants

Immediate Function means that patients leave the office with a functional fixed restoration in place directly after implant insertion.

Osseointegration is defined as a direct structural and functional connection between living bone and the surface of a load-carrying implant.* With the Immediate Function protocol, osseointegration has not yet taken place when abutment and provisional restoration are delivered to the patient. The majority of the scientific publications report on Nobel Biocare TiUnite implants that were performed with Immediate Function resulting in successful outcomes. The TiUnite implants maintain and increase the initial stability over time until the osseointegration takes place. Immediate Function with its potential loading is an alternative to later loading protocols for the experienced implant user.

As with any implant surgical or restorative procedure, the treatment outcome is interdependent upon six variables:

- Biocompatibility of materials
- Implant design
- Implant surface
- Surgical technique
- Prosthetic loading conditions
- Individual patient local site conditions

Patient selection

- Compliant patient with good overall health and oral hygiene.
- Good gingival/periodontal/periapical status of adjacent teeth.
- Favorable and stable occlusal relationship to avoid overload to newly placed implant during initial healing.
- No apical disorder/inflammation at the area of the implant site.
- Sufficient bone volume and density to allow placement of adequate numbers and diameters of implants to withstand potential loads.
- Sufficient bone density to maintain stability throughout osseointegration phase.
- No pronounced bruxism.
- Indicated for all regions as long as selection criteria are met.

For patients not meeting these criterias, an unloaded protocol to achieve secondary stability is still appropriate.

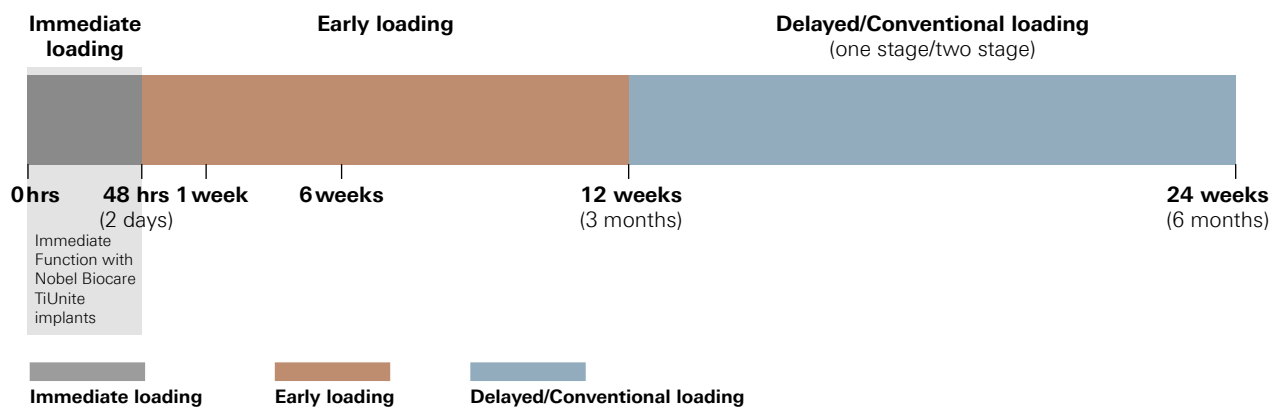
As with any procedure, it is the responsibility of the health-care provider to determine the benefits and risks of Immediate Function compared with delayed loading for a given patient and implant site.

Clinical relevance

- Immediate Function means that patients leave the office with a functional fixed restoration.
 - Immediate loading is an alternative to later loading protocols for the experienced implant user.
 - Careful patient selection is indicated.
-

* Brånemark P-I, Zarb G, Albrektsson T. *Tissue-integrated prostheses: Osseointegration in clinical dentistry*. Chicago: Quintessence Publishing Co., Inc. 1985.

Loading protocols – definitions



Surgical guidelines

- Adapt implant site preparation technique to bone quality/ quantity or use a tapered implant body for high initial implant stability.
- Individual implants should be able to withstand a final tightening torque of minimum 35 Ncm torque without further rotation to confirm stability at time of implant placement.
- If resonance frequency measurement is performed at time of placement – ISQ values > 60 is recommended.
- Regardless of anatomic site or bone quality, implants typically show a drop in the initial stability over the first several weeks before osseointegration takes place. While the maintenance of initial stability is higher with TiUnite than a machined implant surface, this phenomenon can still be expected to occur. Consequently, it is not just the Immediate Function itself but also other prosthetic manipulation of the implant during the healing phase that needs to be considered, e.g. unscrewing of provisional restoration and impression copings.

Restorative guidelines

- A restorative strategy should be developed to ensure minimal handling and tightening of prosthetic components and transference of forces to the implants during the first weeks after placement.
- Special care is recommended when it comes to evaluating load distribution and the elimination of cantilevers and lateral forces. If possible, the occlusal contact should be reduced during the first two to three months after implant placement.
- To obtain optimal esthetics, when practical, the placement of the final abutment at time of implant placement can minimize further disruption of the soft tissue interface.
- A well designed provisional restoration to be used during the maturation of the soft tissue improves the esthetic end results.
- Cantilevers of all types should be avoided in Immediate Function protocol.

Post-surgery and maintenance program

The follow-up and maintenance is the same as for all implant-based treatments with special attention to the following:

- Antibiotics on the day of surgery and some days post-surgery may be indicated.
- Restrict diet to soft food first weeks after implant placement.
- A soft toothbrush used with a chlorhexident gel twice a day for the first few weeks.
- Follow-up visit at individual intervals with examination of the soft tissue, the construction, and the occlusal condition as for all implant cases.

Clinical relevance

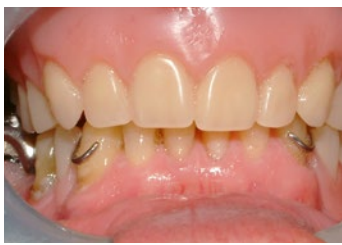- Follow recommended guidelines for successful outcomes.
 - Implant should be able to withstand a tightening torque of minimum 35 Ncm.
 - It is recommended to wait for soft tissue maturation prior to proceeding with final restoration.
-

Mild/moderate bone resorption

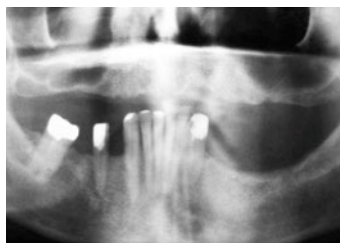Immediate loading for full-arch rehabilitation using NobelClinician

Patient: 65-year-old male, edentulous in the upper jaw. The dentures were made six years ago. **Chief complaint:** Patient was self-conscious of having a removable upper denture. He complained about the decreased retention and was often worried about the falling out of the denture. The patient's requirement was to replace the removable upper denture with a fixed restoration. **Overall health:** Healthy and non-smoker. **Oral examination:** Soft tissues within normal limits. Mild to moderate horizontal and vertical bone resorption patterns, with bilateral posterior sinus pneumatization.

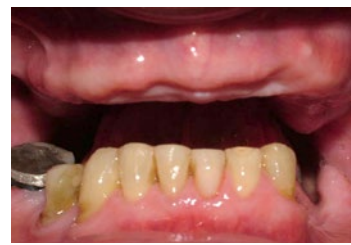Decision: The predecessor of the NobelClinician Software was used for treatment planning, followed by the use of a surgical template for a precise implant placement and a minimally invasive and flapless surgical procedure. Five Brånemark System Mk III Groovy implants and one Nobel-Speedy Shorty implant were placed posteriorly on the left side. As final restoration, a NobelProcera Implant Bridge Titanium with acrylic teeth was used. The final restoration was prepared one day prior to surgery and inserted into the patient's mouth at the time of implant placement. **Time for total treatment:** 3 months



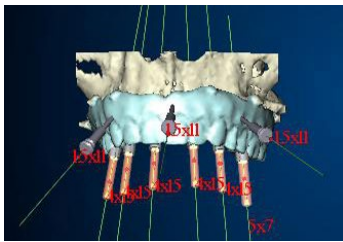
Initial analysis shows the complete maxillary denture with the partial mandibular denture in occlusion. The decreased retention and instability of the maxillary denture lead to its replacement.



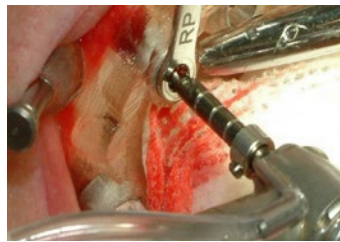
Pre-op panoramic radiograph (OPG) shows the mild to moderate horizontal and vertical bone resorption patterns in maxilla resulting in the instability of the maxillary denture. The bilateral sinus pneumatization is also observed.



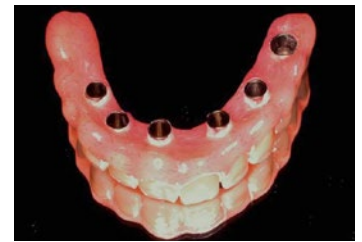The intra-oral analysis shows the healthy condition of the soft tissues. The bone height and width were seen to be adequate for the planned treatment and optimal surgical and restorative outcome.



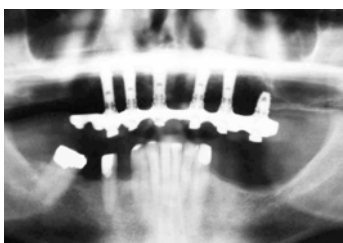
Digital treatment planning done in 2007 with the predecessor of the NobelClinician Software. The reconstructed 3D image of the maxilla allowed for the visualization of quantity and quality of available bone and for digital treatment planning and positioning of the implants relative to the prosthesis.



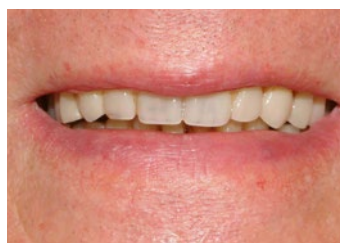The pre-planned surgery was performed with the use of a surgical template to ensure optimal implant placement. The guided sleeves allowed for precise drilling as well as minimal invasiveness of the soft and hard tissues for an optimal surgical outcome.



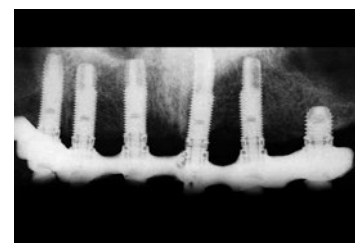
As final restoration, a NobelProcera Implant Bridge Titanium with acrylic teeth was provided to the patient. It was prepared one day prior to surgery and inserted into the patient's mouth at the time of implant placement.



Post-op panoramic radiograph (OPG) immediately after implant placement shows the successful maxillary treatment with six Nobel Biocare implants and a NobelProcera Implant Bridge.



Post-op picture of the patient shortly after surgery. The NobelProcera Implant Bridge provides the patient with the stability and retention he needs, resulting in an increased quality of life.



Post-op radiographs show a follow-up of more than five years. The successful bone maintenance around the implants and the final restoration can be observed both radiographically and clinically, when compared with the post-op radiograph taken immediately after the treatment.

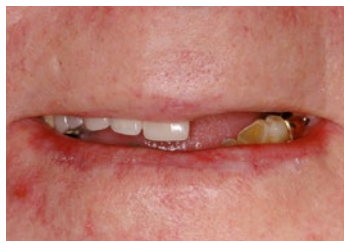Mild/moderate bone resorption

Failing dentition in both arches

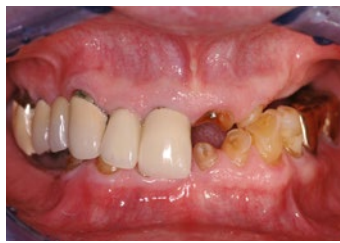Patient: This 68-year-old man had recently lost a left side maxillary anterior fixed partial denture due to extensive caries, and had several other teeth with large carious lesions.

Chief complaint: His principle concerns were the current esthetic presentation and inability to function. He stated he did not want removable prosthetic appliances as part of any future treatment. **Overall health:** Good general health with no contraindications to surgery. **Oral examination:** Unstable occlusion, extensive decay with several unrestorable teeth; periodontal status was fair, with mild to moderate periodontal pocketing and mobility.

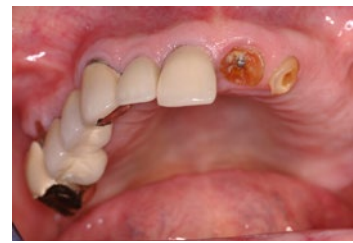Decision: In order to fulfill patient requirements, removal of the remaining teeth and restoration with the All-on-4® treatment concept was advised, thereby avoiding removable prosthetic appliances with immediate loading. As a final restoration, a NobelProcera Implant Bridge Titanium framework with acrylic teeth was used. **Time for total treatment:** 10 months



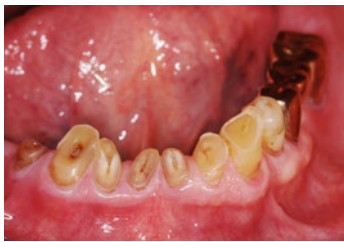Unretracted pre-treatment view shows no visible soft tissue in either arch. Visibility of tissue in the residual ridge is an important aspect of treatment planning, influencing both restorative and surgical approaches.



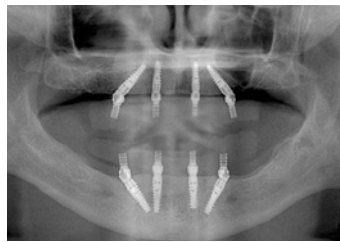
The presenting occlusion was a deep Class II with posterior collapse and over closure.



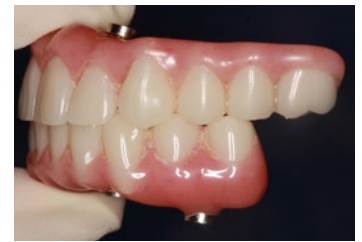The hemi-edentulous arch presented an esthetic and restorative treatment planning challenge if implants are considered unilaterally.



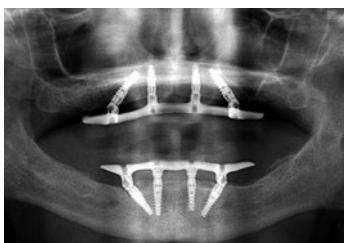Strong vertical bruxing patterns were evident in the mandibular anterior area.



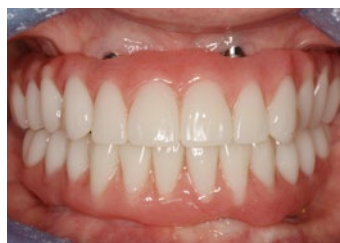The patient requested and consented to removal of remaining teeth with full-arch implant restorations in both jaws. The All-on-4 concept with NobelActive implants was used.



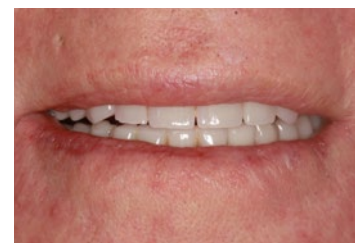Because sufficient initial stability was achieved with each implant, provisional restoration of each arch with immediate function was possible on the day of extraction and implant placement. Cantilever stresses were minimized by reducing the cantilever length of the lower arch.



After six months the final restoration was constructed with a wrap-around design from a precision-milled NobelProcera Implant Bridge. The wrap-around design makes any future modification due to soft tissue movement easier.



Intra-oral view shows the final restorations with first molar occlusion. Acrylic teeth and soft tissue veneering were used to achieve the restorative outcome.



Unretracted smile photograph shows an improved esthetic presentation. Patient has been in successful function for several years and has fulfilled desire to avoid a removable prosthesis in the transition to a fixed implant restoration.

Dental practitioner: Stephen Parel, DDS – United States

Dental technician: Gerry Gaubert – United States

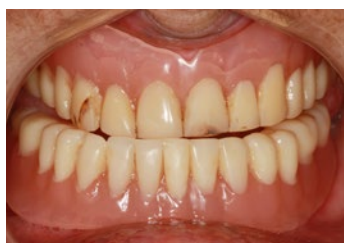Moderate bone resorption

All-on-4® treatment concept with NobelGuide in maxilla and flap approach in mandible providing a complete rehabilitation with a minimally invasive solution

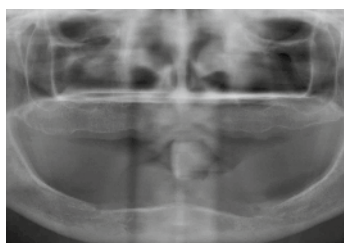
Patient: Total edentulous female patient in her early 50's rehabilitated with upper and lower removable dentures over 15 years ago. **Chief complaint:** Poor retention and stability of the removable dentures with consequent discomfort, insecurity during phonetic and masticatory functions and unsatisfactory esthetics. Her main goal was to obtain a fixed implant-supported rehabilitation. **Overall health:** Healthy patient. **Oral examination:** Moderate bone resorption in the maxilla (at least 5 mm width and 10 mm bone height between the canines in maxilla). Severe bone resorption in the mandible (at least 5 mm width and 8 mm bone height between the mental foramina in mandible). Low smile line.

Decision: Fixed implant-supported bimaxillary rehabilitation with the All-on-4® treatment concept, following the NobelGuide protocol (flapless) in the maxilla and the conventional flap technique with the All-on-4® Guide in the mandible. Four NobelSpeedy Groovy implants were placed in each jaw, followed by immediate placement of provisional fixed all-acrylic bridges providing the patient with Immediate Function solution. In maxilla, a NobelProcera Implant Bridge Titanium framework with individually designed and cemented zirconia crowns with pink acrylic was used. In mandible, a NobelProcera Implant Bridge Titanium framework wrapped in pink acrylic and denture teeth was used.

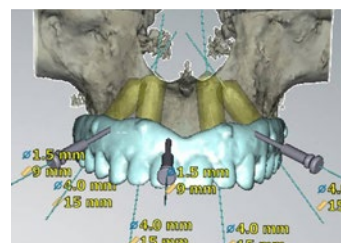
Time for total treatment: 5 months



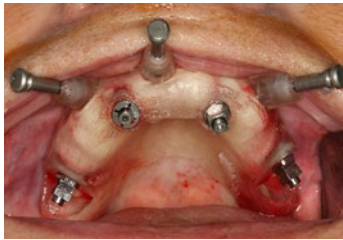
Intra-oral view of the removable dentures. Since they did not meet the functional and esthetic requirements, a new upper removable denture was fabricated. The intra-oral features were evaluated, with special consideration to the low smile line and mouth opening capability of over 50 mm prior to the treatment.



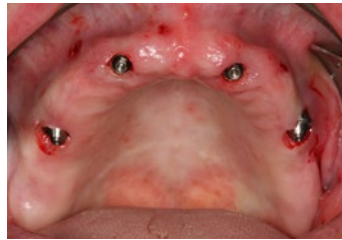Pre-op panoramic radiograph (OPG) together with the 3D radiographic analysis shows the moderate bone resorption in the maxilla and severe bone resorption in the mandible (note the lack of available bone for implant placement in the posterior maxilla and mandible).



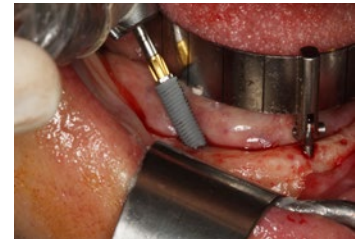
Treatment planning with the NobelClinician Software for a detailed diagnostic process in the maxilla. A prosthetic-driven planning combined with the patient's anatomy and prosthetic needs was required to ensure optimal implant support for an optimal restorative solution.



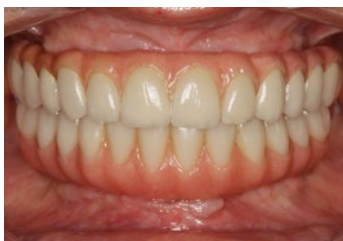In the maxilla, the radiographic guide (removable prosthesis) was stabilized in the patient's mouth with the support of the radiographic index and the double scan technique was done previously. Now using the NobelGuide flapless approach, the surgical template was carefully installed to optimally position the four implants, resulting in a minimally invasive treatment.



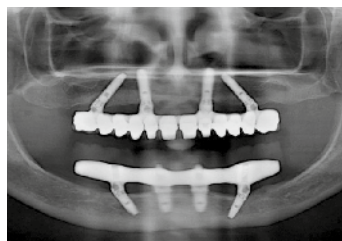
Post-op occlusal view immediately after placement of the four implants and Multi-unit Abutments. The straight Multi-unit Abutments were placed in the axial anterior implants. The 30° Multi-unit Abutments Non-Engaging were placed using a custom jig for the correct positioning of the angulated abutments.



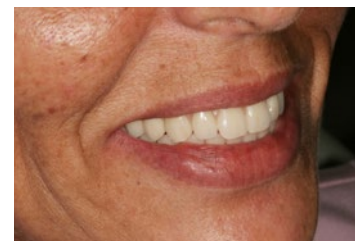After traditional treatment planning in the mandible, a conventional flap procedure was done. The All-on-4® Guide was positioned to facilitate implant placement. The purpose of this surgical guide is to assist in the correct angulations of the posterior implants between 30° to 45°.



The dentures were converted into fixed all-acrylic bridges and were delivered with Temporary Copings Multi-unit Titanium. The provisional bridges were retrofitted manually onto their corresponding Multi-unit Abutments in the patient's mouth immediately after surgery, providing her with Immediate Function.



Post-op panoramic radiograph (OPG) shows successful All-on-4® treatments with four NobelSpeedy Groovy implants in combination with precision-milled NobelProCera Implant Bridges placed in each jaw. The bridges were milled from a solid monobloc of titanium to secure precision of fit and longevity and designed to the patient's esthetic and functional needs.



Extra-oral view of the patient showing the final rehabilitation with fixed bridges to fulfill the phonetic, masticatory and esthetic needs of the patient. The base of the provisional and final bridges were designed to be convex or flat and polished for minimum plaque retention and easy cleaning.

Dental practitioner: Paulo Malo, DDS, PhD – Portugal

Dental laboratory: MALO Ceramics – Portugal

Moderate/severe bone resorption

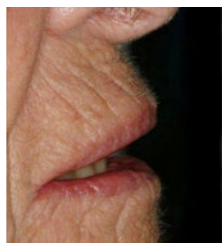A predictable restorative outcome as a result of a pre-treatment evaluation method using NobelClinician

Patient: 73-year-old healthy female, unable to function with her existing maxillary distal extension partial dentures.

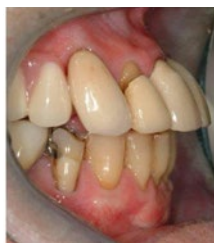Overall health: Unremarkable medical history with exception of Tardive Dyskinesia (involuntary facial muscle movements). **Oral examination:** Remaining anterior maxillary teeth with gross cervical caries and deemed nonrestorable. Displacement of the premaxillary alveolus and remaining maxillary teeth anteriorly due to tongue thrusting habit consistent with Tardive Dyskinesia, resulting in labial incompetence at rest.

Decision: Dentures were not advised due to the excessive tongue thrusting. Removal of the existing maxillary teeth, alveolarplasty to raconteur the premaxilla palatally. Immediate placement of two NobelSpeedy Groovy implants in the anterior and two Brånemark System Zygoma implants in the posterior part of the maxilla, followed by a provisional restoration with Immediate Function protocol. As final restoration, a screw-retained NobelProcera Implant Bridge Titanium framework with acrylic teeth was provided.

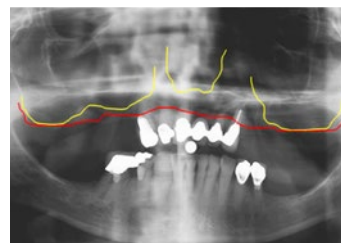
Time for total treatment: 6 months



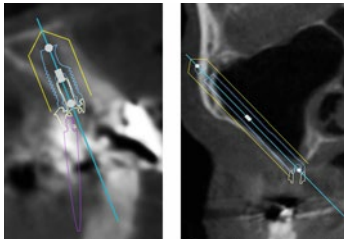
Extra-oral analysis shows the labial incompetence secondary to the displaced premaxilla. The loss of posterior support secondary to severe resorption further contributed to the involuntary movement of the tongue caused by Tardive Dyskinesia.



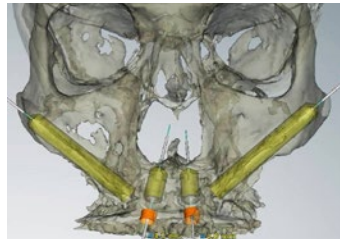
Intra-oral analysis shows the buccal displacement of the premaxilla and the anterior maxillary teeth leading to an increased overjet caused by tongue thrusting.



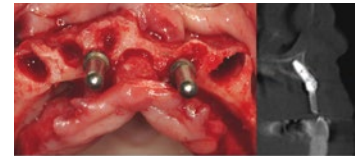
Pre-op panoramic radiograph (OPG) shows the nonrestorable teeth along with the severe bone resorption of the posterior maxilla, making it difficult to place standard implants in that region.



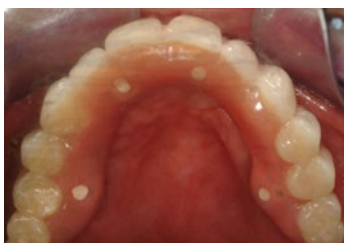Planned virtual positioning of the immediate implants using NobelClinician Software.



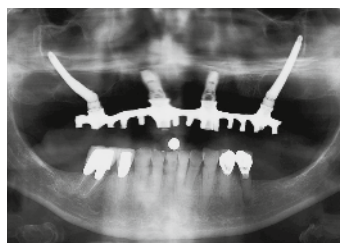
NobelClinician Software was used for enhanced diagnostics and treatment planning. The immediate placement of the NobelSpeedy Groovy implants in the anterior and the Brånemark System Zygoma implants in the posterior part of the maxilla was based on the restorative needs and surgical requirements.



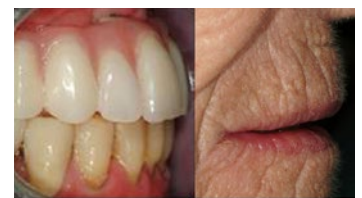Alveolarplasty followed by palatal positioning of the implants as planned in the “virtual surgical planning”. A post-op 3D radiograph demonstrates the final position of the premaxillary implants.



Occlusal view of the final maxillary prosthesis. The optimal emergence of the screw access of the posterior Brånemark System Zygoma implants is a result of the virtual treatment planning favoring the necessary posterior support, which would otherwise not have been possible without bone grafting.



Post-op panoramic radiograph (OPG) shows the NobelSpeedy Groovy implants in the anterior and Brånemark System Zygoma implants in the posterior part of the maxilla using the graftless approach. A NobelProcera Implant Bridge Titanium framework was used to achieve the desired support.



Post-op analysis shows the correction of the anterior maxillary teeth position and the labial incompetence with the support of the final screw-retained NobelProcera Implant Bridge Titanium framework and acrylic teeth.

References

Quality of Life publications

Lundqvist S. et al. Speech before and after treatment with bridges on osseointegrated implants in the edentulous upper jaw. *Clin Oral Implants Res*. 1992; 3(2):57-62

Cibirka RM, Razzoog M, Lang BR. Critical evaluation of patient responses to dental implant therapy. *J Prosthet Dent* 1997;78:574-581

Fiske et al. The emotional effects of tooth loss in edentulous people. *British Journal*, Vol 184, No. 2, January 24, 1998

Melas F, Marcenes W, Wright PS. Oral health impact on daily performance in patients with implant-stabilized overdentures and patients with conventional complete dentures. *Int J Oral Maxillofac Implants* 2001;16(5):700-712

The McGill consensus statement on overdentures. Mandibular two-implant overdentures as first choice standard of care for edentulous patients. Montreal, Quebec, May 24-25, 2002.; *Int J Oral Maxillofac Implants*. 2002 Jul-Aug;17(4):601-2

Awad MA, Lund JP, Shapiro SH, Locker D, Klemetti E, Chehade A, Savard A, Feine JS. Oral health status and treatment satisfaction with mandibular implant overdentures and conventional dentures: a random clinical trial in a senior population. *Int J Prosthodont* 2003;16(4):390-396

Heydecke G, Locker D, Award MA, Lund JP, Feine JS. Oral and general health-related quality of life with conventional and implant dentures. *Comm Dent Oral Epidemiol* 2003;31(3):161-168

Att W, Stappert C. Implant therapy to improve quality of life. *Quintessence Int* 2003;34(8):573-581

Award MA, Lund JP, Dufresne E, Feine JS. Comparing the efficacy of mandibular implant-retained overdentures and conventional dentures among middle-aged edentulous patients: satisfaction and functional assessments. *Int J Prosthodont* 2003;16(2):117-122

Heydecke G. et al. Speech with maxillary implant prostheses: rating of articulation. *J Dent Res*. 2004; 83(3): 236-40

Berretin-Felix G, Nary Filho H, Padovani CR, Machado WM. A longitudinal study of quality of life of elderly with mandibular implant-supported fixed prosthesis. *Clin Oral Implants Res* 2008;19:704-708

Nickenig HJ, Wichmann M, Andreas SK, Eitner S. Oral health-related quality of life in partially edentulous patients: assessments before and after implant therapy. *J Craniomaxillofac Surg*. 2008 36(8):477-80

Hobkirk JA, Abdel-Latif HH, Howlett J, Welfare R, Moles DR. Prosthetic treatment time and satisfaction of edentulous patients treated with conventional or implant-stabilized complete mandibular dentures: a case-control study (part 2). *Int J Prosthodont* 2009;22(1):13-9

Turkylmaz I, Company AM, McGlumphy EA. Should edentulous patients be constrained to removable complete dentures? The use of dental implants to improve quality of life for edentulous patients. *Gerodontology* 2010;27(1):3-10

Felton DA. Edentulism and comorbid factors. *J Prosthodont*. 2009;18(2):88-96. Republished in: *Tex Dent J*. 2010;127(4):389-401

Patient satisfaction publications

Babbush CA. Posttreatment quantification of patient experiences with full-arch implant treatment using a modification of the OHIP-14 questionnaire. *J Oral Implantol*. 2012 Jun;38(3):251-60

Long-term follow-up of edentulous patients

Adell R, Lekholm U, et al. A 15-year study of osseointegrated implants in the treatment of the edentulous jaw. *Int J Oral Surg* 1981;10(6):387-416

Lindquist LW, Carlsson GE, Jemt T. A prospective 15-year follow-up study of mandibular fixed prostheses supported by osseointegrated implants. Clinical results and marginal bone loss. *Clin Oral Implants Res* 1996;7(4):329-36

Friberg B, Grondahl K. Long-term follow-up of severely atrophic edentulous mandibles reconstructed with short Brånemark implants. *Clin Implant Dent Relat Res* 2000;2(4):184-9

van Steenberghe D, Quirynen M, et al. Marginal bone loss around implants retaining hinging mandibular overdentures, at 4-, 8- and 12-years follow-up. *J Clin Periodontol* 2001;28(7): 628-633

Jemt, T, Johansson J. Implant treatment in the edentulous maxillae: a 15-year follow-up study on 76 consecutive patients provided with fixed prostheses. *Clin Implant Dent Relat Res* 2006; 8(2): 61-69

Astrand P, Ahlqvist J, Gunne J, Nilson H. Implant treatment of patients with edentulous jaws: a 20-year follow-up. *Clin Implant Dent Relat Res* 2008;10(4):207-17

All-on-4® treatment concept

Krekmanov L, Kahn M, Rangert B, Lindstrom H. Tilting of posterior mandibular and maxillary implants for improved prosthesis support. *Int J Oral Maxillofac Implants* 2000;15(3):405-14

Aparicio C, Perales P, Rangert B. Tilted implants as an alternative to maxillary sinus grafting: a clinical, radiologic, and periotest study. *Clin Implant Dent Relat Res* 2001;3(1):39-49

Malo P, Rangert B, Nobre M. "All-on-Four" immediate-function concept with Branemark System implants for completely edentulous mandibles: a retrospective clinical study. *Clin Implant Dent Relat Res* 2003;5 Suppl 1:2-9

Malo P, Rangert B, Nobre M. All-on-4 immediate-function concept with Branemark System implants for completely edentulous maxillae: a 1-year retrospective clinical study. *Clin Implant Dent Relat Res* 2005;7 Suppl 1:S88-S94

Malo P, Nobre Mde A, Petersson U, Wigren S. A pilot study of complete edentulous rehabilitation with immediate function using a new implant design: case series. *Clin Implant Dent Relat Res* 2006;8(4):223-32

Malo P, de Araujo Nobre M, Lopes A. The use of computer-guided flapless implant surgery and four implants placed in immediate function to support a fixed denture: preliminary results after a mean follow-up period of thirteen months. *J Prosthet Dent* 2007;97(6 Suppl):S26-S34

Pomares C. A retrospective clinical study of edentulous patients rehabilitated according to the 'all on four' or the 'all on six' immediate function concept. *Eur J Oral Implantol* 2009;2(1):55-60

Agliardi E, Panigatti S, Clerico M, Villa C, Malo P. Immediate rehabilitation of the edentulous jaws with full fixed prostheses supported by four implants: interim results of a single cohort prospective study. *Clin Oral Implants Res* 2010;21(5):459-65

Agliardi E, Clerico M, Ciancio P, Masironi D. Immediate loading of full-arch fixed prostheses supported by axial and tilted implants for the treatment of edentulous atrophic mandibles. *Quintessence Int* 2010;41(4):285-93

Malo P, de Araujo Nobre M, Lopes A, Moss SM, Molina GJ. A longitudinal study of the survival of All-on-4 implants in the mandible with up to 10 years of follow-up. *J Am Dent Assoc* 2011;142(3):310-20

Babbush C, Kutsko G, Brokloff J. The All-on-Four Immediate function treatment concept with NobelActive implants- A retrospective study. *J Oral Implantol* 2011;37(4):431-45

Francetti L, Romeo D, Corbella S, Taschieri S, Del Fabbro M. Bone Level Changes Around Axial and Tilted Implants in Full-Arch Fixed Immediate Restorations. Interim Results of a Prospective Study. *Clin Implant Dent Relat Res* 2012;14(5):646-54

Weinstein R, Agliardi E, Fabbro MD, Romeo D, Francetti L. Immediate rehabilitation of the extremely atrophic mandible with fixed full-prosthesis supported by four implants. *Clin Implant Dent Relat Res* 2012;14(3):434-41

Malo P, de Araujo Nobre M, Lopes A, Francischone C, Rigolizzo M. "All-on-4" Immediate-Function Concept for Completely Edentulous Maxillae: A Clinical Report on the Medium (3 Years) and Long-Term (5 Years) Outcomes. *Clin Implant Dent Relat Res* 2012;14 Suppl 1:e139-50

- Galindo DF, Butura CC. Immediately loaded mandibular fixed implant prostheses using the All-on-Four protocol: A report of 183 consecutively treated patients with 1 year of function in definitive prostheses. *The International Journal of Oral & Maxillofacial Implants* 2012;27(3):628-33
- Babbush C, Brokloff J. A Single-Center Retrospective Analysis of 1001 Consecutively Placed NobelActive Implants. *Implant Dent* 2012;21(1):28-35
- Mozzati, M et al. Immediate Postextractive Dental Implant Placement with Immediate Loading on Four Implants for Mandibular-Full-Arch Rehabilitation: A Retrospective Analysis. *Clin Implant Dent Relat Res*, epub ahead 2012
- Brånemark System® Zygoma**
- Stevenson AR, Austin BW. Zygomatic fixtures—the Sydney experience. *Ann R Australas Coll Dent Surg* 2000;15:337-9
- Bedrossian E, Stumpel LJ, 3rd. Immediate stabilization at stage II of zygomatic implants: rationale and technique. *J Prosthet Dent* 2001;86(1):10-14
- Nkenke E, Hahn M, Lell M, Wiltfang J, Schultze-Mosgau S, Stech B, et al. Anatomic site evaluation of the zygomatic bone for dental implant placement. *Clin Oral Implants Res* 2003;14(1):72-9
- Branemark PI, Grondahl K, Ohnrell LO, Nilsson P, Petruson B, Svensson B, et al. Zygoma fixture in the management of advanced atrophy of the maxilla: technique and long-term results. *Scand J Plast Reconstr Surg Hand Surg* 2004;38(2):70-85
- Malevez C, Abarca M, Durdu F, Daelemans P. Clinical outcome of 103 consecutive zygomatic implants: a 6-48 months follow-up study. *Clin Oral Implants Res* 2004;15(1):18-22
- Bedrossian E, Rangert B, Stumpel L, Indresano T. Immediate function with the zygomatic implant: a graftless solution for the patient with mild to advanced atrophy of the maxilla. *Int J Oral Maxillofac Implants* 2006;21(6):937-42
- Chow J, Hui E, Lee PK, Li W. Zygomatic implants—protocol for immediate occlusal loading: a preliminary report. *J Oral Maxillofac Surg* 2006;64(5):804-11
- Aparicio C, Ouazzani W, Garcia R, Arevalo X, Muela R, Fortes V. A prospective clinical study on titanium implants in the zygomatic arch for prosthetic rehabilitation of the atrophic edentulous maxilla with a follow-up of 6 months to 5 years. *Clin Implant Dent Relat Res* 2006;8(3):114-22
- Davo R, Malevez C, Rojas J. Immediate function in the atrophic maxilla using zygoma implants: a preliminary study. *J Prosthet Dent* 2007;97(6 Suppl):S44-S51
- Davo R, Malevez C, Rojas J. Immediate function in the atrophic maxilla using zygoma implants: a preliminary study. *J Prosthet Dent* 2007;97(6 Suppl):S44-S51
- Balshi SF, Wolfinger GJ, Balshi TJ. A retrospective analysis of 110 zygomatic implants in a single-stage immediate loading protocol. *Int J Oral Maxillofac Implants* 2009;24(2):335-41
- Bedrossian E. Rehabilitation of the Edentulous Maxilla with the Zygoma Concept: A 7-year Prospective Study. *Int J Oral Maxillofac Implants* 2010;25(6):1213-21
- Aparicio C, Manresa C, Francisco K, Ouazzani W, Claros P, Potau JM. The Long-Term Use of Zygomatic Implants: A 10-Year Clinical and Radiographic Report. *Clin Implant Dent Relat Res* 2012 [Epub ahead of print]
- Edentulous treatments with guided approach**
- Sanna AM, Molly L, van Steenberghe D. Immediately loaded CAD-CAM manufactured fixed complete dentures using flapless implant placement procedures: a cohort study of consecutive patients. *J Prosthet Dent* 2007;97(6):331-9
- Meloni SM et al. Implant treatment software planning and guided flapless surgery with immediate provisional prosthesis delivery in the fully edentulous maxilla. A retrospective analysis of 15 consecutively treated patients. *Eur J Oral Implantol* 2010;3(3):245-51
- Gillot L, Noharet R, Cannas B. Guided surgery and presurgical prosthesis: preliminary results of 33 fully edentulous maxillae treated in accordance with the NobelGuide protocol. *Clin Implant Dent Relat Res* 2010;12 Suppl 1:e104-13
- Immediate Function with TiUnite® implants**
- Schnitman PA, Wohrle PS, Rubenstein JE, DaSilva JD, Wang NH. Ten-year results for Branemark implants immediately loaded with fixed prostheses at implant placement. *Int J Oral Maxillofac Implants* 1997;12(4):495-503
- Glauser R, Portmann M, Ruhstaller P, Lundgren AK, Hammerle CH, Gottlow J. Stability measurements of immediately loaded machined and oxidized implants in the posterior maxilla. A comparative clinical study using resonance frequency analysis. *Appl Osseointegration Res* 2001;2:27-29
- Glauser R, Zembic A, Ruhstaller P, Windisch S. Five-year results of implants with an oxidized surface placed predominantly in soft quality bone and subjected to immediate occlusal loading. *J Prosthet Dent* 2007;97(6 Suppl):S59-S68
- Marzola R, Scotti R, Fazi G, Schincaglia GP. Immediate loading of two implants supporting a ball attachment-retained mandibular overdenture: a prospective clinical study. *Clin Implant Dent Relat Res* 2007;9(3):136-43
- Güncü MB, Aslan Y, Tümer C, Guncu GN, Uysal S. In-patient comparison of immediate and conventional loaded implants in mandibular molar sites within 12 months. *Clin Oral Implants Res* 2008;19(4):335-41
- Schincaglia GP, Marzola R, Giovanni GF, Chiara CS, Scotti R. Replacement of mandibular molars with single-unit restorations supported by wide-body implants: immediate versus delayed loading. A randomized controlled study. *Int J Oral Maxillofac Implants* 2008;23(3):474-80
- Raghoebar GM, Slater JJ, Hartog L, Meijer HJ, Vissink A. Comparison of procedures for immediate reconstruction of large osseous defects resulting from removal of a single tooth to prepare for insertion of an endosseous implant after healing. *Int J Oral Maxillofac Surg* 2009;38(7):736-43
- Kielbassa AM, Martinez-de Fuentes R, Goldstein M, Arnhart C, Barlattani A, Jackowski J, et al. Randomized controlled trial comparing a variable-thread novel tapered and a standard tapered implant: interim one-year results. *J Prosthet Dent* 2009;101(5):293-305
- Liddel G, Henry P. The immediately loaded single implant-retained mandibular overdenture: a 36-month prospective study. *Int J Prosthodont* 2010;23(1):13-21
- Shibly O, Patel N, Albandar JM, Kutkut A. Bone Regeneration Around Implants in Periodontally Compromised Patients: A Randomized Clinical Trial of the Effect of Immediate Implant With Immediate Loading. *J Periodontol* 2010;81(12):1743-51
- Glauser R. Implants with an Oxidized Surface Placed Predominately in Soft Bone Quality and Subjected to Immediate Occlusal Loading: Results from a 7-Year Clinical Follow-Up. *Clin Implant Dent Relat Res* 2011 [Epub ahead of print]

